



**PATIENT**

Willow Price

**SPECIES**

Feline

**BREED**

DSH

**SEX**

Female Spayed

**AGE**

5.6.11

**WEIGHT**

8.6lbs

**INTERPRETED BY**

Maggie Machen Lamy,  
DVM, DACVIM  
(Cardiology)

**HOSPITAL NAME**

Fullerton Animal  
Hospital

**REFERRING VET**

Dr. Levine

**INVOICE**

26155

**DATE**

9.1.22

**PRESENTING CLINICAL SIGNS**

History: Grade 3 murmur auscultated on 8/26 and marked elevation in ProBNP.

-Current medications: Topical Bravecto.

-Sedation used: Not required to complete full diagnostic ultrasound.

-Pertinent previous ultrasound results: No previous.

-STAT: Not requested

-Imaging performed by: Andi Parkinson, BS, RDMS.

**ECHOCARDIOGRAM FINDINGS**

2D, m-mode, color flow and doppler imaging is available. The left ventricular wall is mild to moderately hypertrophied. There is a diffusely hyperechoic endocardium consistent with fibrosis and ventricular remodeling. Mild papillary muscle remodeling. The right ventricle is subjectively normal in size and morphology. There is no left atrial enlargement present. No right atrial enlargement present. Normal RVOT velocity. Mild systolic anterior motion (SAM) of the mitral valve present, with an elevated dynamic LVOT velocity. There is mild eccentric mitral regurgitation present secondary to SAM. No other significant valvular regurgitation is present. There is no pericardial effusion noted. No pleural effusion appreciated. No obvious cardiac tumors.

**CARDIAC CHART**

FELINE CARDIAC PARAMETERS	BODY WEIGHT (kg)	HR (BPM)	IVSd (cm) <small>(Moise, Pipers)</small>	LVIDd (cm) <small>(Moise, Pipers)</small>	LVWd (cm) <small>(Moise, Pipers)</small>	FS (%)	EF (%)
NORMAL PARAMETER	-----	150-240	3.5-0.55	<2 (mean 1.5)	3.5-0.55	35-67	80-100
PATIENT	3.9	190	0.68	1.2	0.75	35	68
FELINE CARDIAC PARAMETERS	LA/AO <small>(Boon)</small>	LA/AO HEART BASE (Swe) <small>(Abbott)</small>	LA 2D short axis Base view (cm) <small>(Abbott)</small>	LVOT VEL (m/s)	RVOT VEL (m/s)	E max (m/s)	
NORMAL	<1.5	<1.3	<1.2	<1.6	<1.3	<0.9	
PATIENT	NM	1.3	1.26	3.4	1.2	NM	

Adapted from June Boon, Veterinary Echocardiography, 1998  
Abbott J & MacLean H JVIM 2006;20: 111-119, Moise et al. Am J Vet Res 47:1476, 1986. Pipers et al. Am J Vet Res 40:882, 1979.

### INTERPRETATION OF THE FINDINGS & FURTHER RECOMMENDATIONS

The diagnosis is hypertrophic obstructive cardiomyopathy (HOCM). This indicates LV thickening (mild to moderate in this case) with a dynamic LVOT obstruction (SAM) and secondary mitral regurgitation as the cause of the heart murmur. The hypertrophy and obstruction are both mild. There is no left atrial enlargement present, indicating the risk of spontaneous CHF and/or a thrombotic event is currently low. No additional issues are identified.

While no medications have been shown to definitively alter long term outcome at this stage of disease, atenolol is often initiated to decrease the outflow obstruction. If the patient is easily medicated, it is reasonable to initiate at this time as below. If there is difficulty medicating at home, an alternative approach would be closely monitoring for progression in the next 6-12 months. Discussion with the owner is advised. No additional medications are indicated prior to significant atrial dilation.

Monitor at home for any respiratory signs or blood clot events (neurologic change, paralysis, etc.). Anesthetic risk is considered mild, however judicious IV fluid rates are advised to avoid fluid overload. Additionally, drugs that stimulate heart rate should be avoided unless clinically necessary (ketamine, glycopyrrolate, atropine).

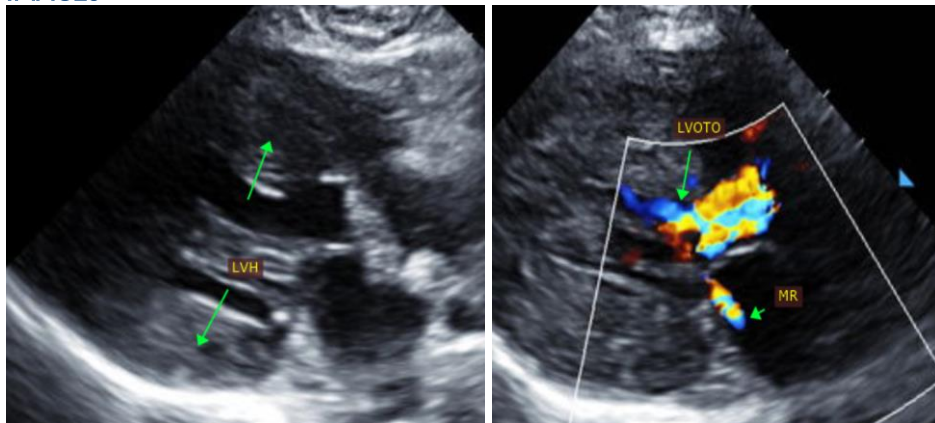
### PLAN

If elected, administer titrating dose of atenolol: 25mg tablets; Give ¼ tab once daily. Recheck heart rate in 1-2 weeks with target stressed rate of 140-160bpm 12-24 hours post-administration. Increase as needed until target reached.

Screening blood pressure and T4 are recommended every 6 months.

Recommend recheck echocardiogram in 6 months to assess for progression, sooner if clinical issues arise.

### IMAGES



The information and recommendations provided are based on the images presented by the referring veterinarian. No evaluation can be communicated regarding pathology that was not visible in the image/video clips provided.

Thank you for this referral. This report was generated using transcription software, and minor dictation errors may be present. If the clinical or image interpretation does not parallel your findings or if I can be of any further assistance, please contact me.

**Maggie Machen Lamy, DVM**  
Diplomate of the American College of Veterinary Internal Medicine (Cardiology)  
info@sonopath.com